

Rhizophora apiculata Bark Ethanolic Extracts Prevent Kidney Damage Caused by Cigarette Smoke in Male Rats

Syazili Mustofa^{1*}, Sarasmita Nirmala Dewi²

¹Departemen of Biochemistry, Molecular Biology and Physiology, Faculty of Medicine, Universitas Lampung, Bandar Lampung, Indonesia

²Medical Profession Program, Faculty of Medicine, Universitas Lampung, Bandar Lampung, Indonesia

*E-mail: syazili.mustofa@fk.unila.ac.id

Rhizophora apiculata mangrove bark contains high levels of antioxidants, including triterpenoids, steroids, saponins, and tannins. The high antioxidant content can prevent oxidative stress, one of which is caused by free radicals from cigarette smoke. This research aimed to determine the potential of Rhizophora apiculata mangrove bark to protect against damage to the kidney organs of male white rats (*Rattus norvegicus*) of the Sprague-Dawley strain exposed to cigarette smoke. This study used 25 mice divided into 5 groups for 30 days, namely group K(-), which was not given exposure to cigarette smoke and mangrove bark extract; group K(+), which was only given exposure to cigarette smoke; group P1, which was given the extract mangrove bark with a dose of 26.27 mg/kg BW and given exposure to cigarette smoke 24 cigarettes per day, group P2 which was given mangrove bark extract with a dose of 56.55 mg/kg BW and given exposure to cigarette smoke 24 cigarettes per day, and group P3 which was given mangrove oil bark extract at a dose of 113.1 mg/kg BW and given exposure to cigarette smoke 24 cigarettes per day. On day 31, the rats were euthanized, and their kidneys were prepared for histology. Kidney histology was observed, and kidney damage was assessed from the histology of glomerular and renal tubular damage. The kidney damage score is 0 if there was no damage, 1 if inflammatory cell infiltration was found, 2 if Bowman space edema or swelling of tubular epithelial cells was found, 3 if necrosis was found. Then, take the average of each renal tubular and glomerular damage score and add them together for a total damage score, namely 0-6. The median kidney damage score in the K (-) group was 0.4, the K (+) group was 3.6, the P1 group was 2.4, the P2 group was 2.4, and the P3 group was 2.2. The results of the Kruskal-Wallis test obtained a p-value of 0.001, meaning there were significant differences in at least the two treatment groups. This research showed that administering Rhizophora apiculata mangrove bark extract could prevent histological damage to the kidneys of male white rats of the Sprague-Dawley strain caused by cigarette smoke.

Keywords: Cigarette Smoke, Ethanolic extract, Kidney Damaged, Mangrove, Rhizophora apiculata Bark

1. Introduction

Indonesia's mangrove forests are the most extensive in the world. The area of mangrove forests in Indonesia is 27% of the total mangrove forests spread across the globe or 75% in Southeast Asia.¹ The area of mangrove forests in Indonesia is around 4,251,011.03 hectares. The number of species is more than 45 species, with a distribution of 15.46% in Sumatra, 2.35% in Sulawesi, 2.35% in Maluku, 9.02% in Kalimantan, 1.03% in Java, 0.18% in Bali and Nusa Tenggara, and 69.43% in Papua. The extent of mangrove forests in

Indonesia is followed by the many types of mangroves found in Indonesia. The kinds of mangrove trees found in Indonesia include *Avicennia* sp, *Sonneratia* sp, *Rhizophora* sp, *Bruguiera* sp, and *Ceriops* sp. One of Indonesia's mangrove forest ecosystem plants is *Rhizophora apiculata*.²

The bark of *Rhizophora apiculata* contains high levels of antioxidants, including triterpenoids, steroids, saponins, and tannins. In the bark of mangroves, tannins have the most increased antioxidant activity.³ This high

level of antioxidants can prevent oxidative stress.⁴

Oxidative stress is an imbalance between free radicals and antioxidants in the body. Oxidative stress causes damage to the body due to increased Reactive Oxygen Species (ROS) as a response to stressors. The negative impact of ROS that arises can damage cell components throughout the body, including nephron cells in the kidneys. Free radical levels in the body can increase due to exposure to cigarette smoke from outside.⁵

Indonesia is the third country in the world with the highest number of smokers after China and India. According to Riskesdas data, the proportion of smokers in Indonesia was 29.3% in 2013. The high number of smokers in Indonesia can have an impact on increasing the incidence of smoking-related diseases, which end in death.⁶

One of the diseases caused by smoking is chronic kidney failure. Smoking can increase the incidence of chronic kidney failure. Passive smokers have a 3x higher chance of experiencing chronic kidney failure compared to non-smokers. Meanwhile, the opportunity for active smokers to experience chronic kidney failure compared to non-smokers is 7x higher.⁷ There is a significant relationship between smoking activity and the incidence of chronic kidney failure in pre-elderly and elderly patients. Chronic kidney failure patients on hemodialysis who have a history of smoking have a risk of chronic kidney failure that is two times greater than patients without a history of smoking. Smoking activates the sympathetic nervous system acutely, which can cause tachycardia and an increase in systolic blood pressure of as much as 21 mmHg. This is due to vasoconstriction in various blood vessels, including blood vessels in the kidneys, which can disrupt renal blood flow, increase renovascular retention, and decrease the Glomerular Filtration Rate. Acute exposure to cigarette smoke can cause an 11% increase in

renovascular resistance, which is accompanied by a 15% decrease in GFR.⁸ For these reasons, researchers were interested in examining the effect of administering *Rhizophora apiculata* mangrove bark extract on the renal histopathology of male white rats (*Rattus norvegicus*) of the Sprague-Dawley strain exposed to cigarette smoke.

2. Methods

This type of research is true experimental quantitative analytical research, using a post-test research design with a sample randomized control group design. This research has obtained research ethics permission from the Research Ethics Commission of the Faculty of Medicine, University of Lampung, number 072/UN26.18/PP.050.02.00/2019.

Experimental animal maintenance was performed at the Animal House, Faculty of Medicine, University of Lampung. Preparations were made and observed at the Histology-Anatomical Pathology Laboratory, Faculty of Medicine, University of Lampung. The samples for this study were male white rats of the Sprague-Dawley strain, 10 to 12 weeks old, weighing 250 grams, obtained from the Palembang Rat Center. A total of 25 male white mice were randomly selected and divided into 5 groups. Providing cigarette smoke using 24 clove cigarettes per day. Rats were divided into 5 groups, namely group (K-): negative control group, given standard food and drink ad libitum for 30 days; positive control group (K+), given regular feed and drink ad libitum and given exposure to cigarette smoke 24 cigarettes/day; treatment group 1 (P1), assigned standard feed and drink ad libitum, given exposure to cigarette smoke 24 cigarettes/day and mangrove bark extract at a dose of 27.55/kg BW; treatment group 2 (P2) was assigned standard feed and drink ad libitum, given exposure to cigarette smoke 24 cigarettes/day and mangrove oil bark extract at a dose of 55.56/kg BW; and treatment group

3 (P3) was given standard feed and drink ad libitum, given exposure to cigarette smoke 24 cigarettes/day and mangrove oil bark extract at a dose of 113.1/kg BW.⁹⁻¹¹

Mangrove plants were taken from the East Lampung coast. The bark was separated from the stem, washed, cut into pieces, and dried. Dried pieces of mangrove bark were ground in a grinding machine until they became powder. The mangrove bark powder was then sieved using a 40-mesh sieve and then soaked in 95% ethanol solvent with a ratio of 1:4 (1kg mangrove bark powder: 4 liters of 95% ethanol) for the first 6 hours, stirred, and then soaked (macerated) for 18 hours. The resulting mixture with 95% ethanol solvent was filtered with filter paper to obtain the filtrate. The filtrate obtained was evaporated using a rotatory evaporator at 50°C. The dried mangrove bark extract was weighed, and the volume and specific gravity were obtained. Then, dilution was carried out, and the dose used in the research was obtained.⁹⁻¹¹

Kidney damage was assessed from the histology of glomerular and renal tubular damage. In scoring the glomerulus of the kidney, if the structure was normal, it was given a score of 0; if there was inflammatory cell infiltration, it was given a score of 1; if there was Bowman space edema, it was given a score of 2, or if there was necrosis, it was given a score of 3. In scoring of the renal tubules, if it looked normal, it was given a score of 0; If there was inflammatory cell infiltration, a score of 1 was given; there was tubular epithelial cell edema, a score of 2, or if there was necrosis, a score of 3. Scoring for the degree of kidney damage is taken from 5 visual fields with the highest glomerular or tubular damage from that field of view, and then the score was determined. Then, take the average of each renal tubular and glomerular damage score and add them together for a total damage score, namely 0-6.¹² Data processing and analysis using SPSS software on a computer, univariate tests, and bivariate tests were carried out using the Kruskal-Wallis test.

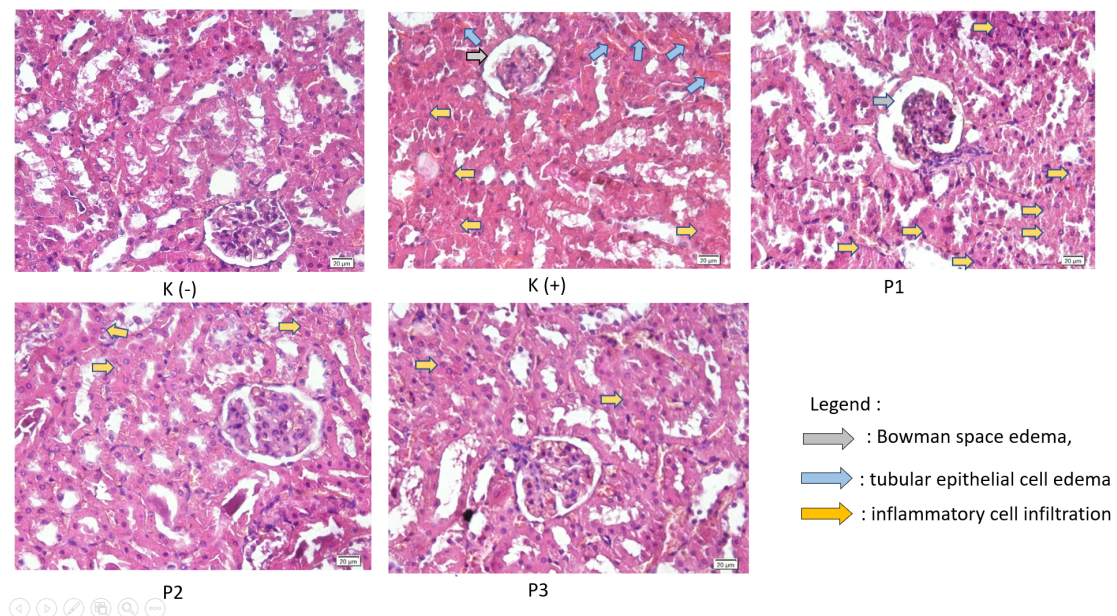


Figure 1. Renal damage by cigarette smoking in rats and the effect of giving ethanol extract of *Rhizophora apiculata* stem bark. The microscopic appearance of the kidneys from the treatment group that received the extract (P1, P2, P3) was generally better than that of the group that was only exposed to cigarette smoke (K+)

3. Result

The results of the renal histology examination can be seen in Figure 1. The examination was carried out using a light microscope with 400x magnification. The control group still had a normal microscopic appearance, and no inflammatory cell infiltration was found. No edema was found in the tubules and Bowman's space. No congestion or necrosis was found. Observations in the K (+) group showed swelling in the tubules, which was characterized by swelling of the cytoplasm and fading of the color of the cell nuclei. In the glomerulus, Bowman's space edema appeared, and a small amount of inflammatory cell dust was found. There also appears to be congestion. The examination results in the P1 group showed swelling of the renal tubules; the renal glomeruli still showed a widening of Bowman's space, although the widening that occurred was not as severe as in the K(+) group. Congestion still appeared, but it was not as massive as in the K (+) group. The microscopic appearance of the kidneys from group P2 showed that there was still tubular swelling and glomerular Bowman space edema, but it was not as massive as in group P1. The results of the microscopic examination of the kidneys from group P3 still found swelling in a small part of the tubules and glomeruli, but in general, they were better compared to group P2. There was no visible congestion or necrosis.

Table 1. Kidney damages scoring

	Rats					Median score(Min-Max)
	1	2	3	4	5	
K-	0	0.4	0	0.8	0.4	0.4 (0-0.8)
K+	4	3	3.6	3.6	3.6	3.6 (3-3.6)
P1	2.4	2.4	3.2	3.2	2.4	2.4 (2.4-3.2)
P2	2.4	2.8	2.2	2.4	2.4	2.4 (2.2-2.8)
P3	2.6	2.8	2.2	1.6	1.8	2.2 (1.6-2.8)

The average kidney damage scoring can be seen in Table 1. The K (+) group had the highest kidney damage scoring. Meanwhile, the treatment groups given *Rhizophora apiculata* bark extract had a lower kidney damage score than the K (+) group. The data was processed using the Kruskal-Wallis test, and a p-value = 0.001 was obtained. Then, the Mann Whitney Post-Hoc test was carried out to see the mean differences between groups, which can be seen in Table 2.

Table 2. Post-Hoc Mann-Whitney test (* significantly different)

Groups	K (-)	K (+)	P1	P2	P3
K (-)	-	0.008*	0.008*	0.008*	0.008*
K (+)	0.008*	-	0.024*	0.007*	0.008*
P1	0.008*	0.024*	-	0.238	0.168
P2	0.008*	0.007*	0.238	-	0.456
P3	0.008*	0.008*	0.168	0.456	-

From table 2 it can be seen that the K(-) value has a significant difference from the K (+), P1, P2, and P3 groups. The scoring of the K (+) group had a significant difference from the K (-) group, meaning that exposure to 24 cigarettes of cigarette smoke for 30 days was proven to damage the microscopic structure of the kidneys in rats. The scoring of the K (+) group had a significant difference from groups P1, P2, and P3, meaning that administration of *Rhizophora apiculata* stem bark ethanol extract was able to prevent kidney damage caused by exposure to cigarette smoke. P1 scoring did not have a significant difference with groups P2 and P3, P2 and P3 scoring also did not have a significant difference, meaning that increasing the dose of *Rhizophora apiculata* bark extract did not increase the protective effect of this extract in preventing kidney damage due to exposure to cigarette smoke.

4. Discussion

The K (+) group had a much higher kidney damage score than the K (-) group. This proves that continuous exposure to cigarette smoke can damage the kidneys. Cigarette smoke, as a source of exogenous free radicals, increases free radicals in the body.¹³ Nicotine reduced the survival of human kidney cells and triggered the production of reactive oxygen species (ROS). In addition, nicotine markedly enhanced the expression of the alpha7 nicotinic acetylcholine receptor ($\alpha 7nAChR$). Nicotine triggered the activation of the NLRP6 inflammasome and caused endoplasmic reticulum (ER) stress. Nicotine induced moderate programmed cell death and tissue damage, but elicited substantial cellular self-digestion in human kidney cells. Furthermore, nicotine stimulated the activation of the NLRP6 inflammasome and autophagy through the $\alpha 7nAChR$ receptor. Nicotine induces renal injury in an animal model via altering the activity of $\alpha 7nAChR$, NLRP6 inflammasome, ER stress, and autophagy.¹⁴

The kidney damage scores in groups P1, P2, and P3 significantly differed from those in group K (+). Groups P1, P2, and P3 were treatment groups that were exposed to cigarette smoke and also given mangrove bark ethanol extract in varying doses every day for 30 days. This proves that the ethanol extract of *Rhizophora apiculata* bark can protect the kidneys from damage due to exposure to cigarette smoke.

Rhizophora apiculata bark extract has high antioxidant activity in inhibiting the formation of free radicals. This is due to the content of antioxidant compounds and phenolic compounds such as flavonoids in the bark. The bark of *Rhizophora apiculata* also contains

tannins, which are useful as a source of exogenous antioxidants. Tannin is an active secondary metabolite compound that is known to have several properties, namely as an astringent, anti-diarrhea, anti-bacterial, and antioxidant. Our previous research reported that *Rhizophora apiculata* bark extract was also able to prevent damage to the rat's testis, pancreas, liver, heart, and lungs due to exposure to cigarette smoke.^{9,11,15,16}

The decrease in kidney damage scores in the treatment group compared to the positive control group was caused by the antioxidant content found in mangrove bark. Free radicals in cigarette smoke have one or more unpaired electrons in their outermost orbitals. In an effort to fill the shortage of electron pairs, free radicals with unpaired electrons will quickly attract electrons from surrounding biological macromolecules such as proteins, nucleic acids, and deoxyribonucleic acid (DNA). If the oxidized and degraded macromolecules are part of cells or organelles, they can cause damage to kidney cells.¹⁷ Exogenous antioxidants are known to be able to inhibit oxidation reactions by giving their electrons to free radicals so that the free radicals become stable molecules and stop causing the cell damage they cause. *Rhizophora apiculata* exhibited the presence of many phytochemicals including xanthoprotein, steroids, tannins, glycosides, reducing sugar, carbohydrates, sterols, terpenoids, phenol, cardioglycosides, and flavonoids.¹⁸ These phytochemical ingredients are able to carry out their role as exogenous antioxidants, so they are able to neutralize free radicals contained in cigarette smoke.

Rhizophora apiculata exhibited higher total phenolic content and antioxidant capacity compared to *Sonneratia alba*. The values of roots had a

larger magnitude compared to those of stems and leaves. Acetone and methanol extracts yielded higher levels. The vinegar derived from Rhizophora wood during the process of charcoal manufacturing exhibited greater potency prior to distillation compared to its potency after distillation. The Rhizophora apiculata wood vinegar exhibited antioxidant qualities that were either stronger or comparable to those of black Camellia sinensis tea, as determined by its total phenolic content, antioxidant capacity, and ferric reducing power. The presence of a significant amount of tannins in Rhizophora bark is responsible for its strong antioxidant properties.¹⁹

5. Conclusion

Administration of Rhizophora apiculata mangrove bark extract starting from a dose of 27.55 mg/kg BW can prevent histopathological damage to the kidneys of male white rats of the Spargue-Dawley strain caused by cigarette smoke. This extract has the potential to be used as an antioxidant supplement to prevent the adverse effects of exposure to cigarette smoke.

References

1. Arifanti VB, Kauffman JB, Subarno S, Ilman M, Tosiani A, Novita N. Contributions of mangrove conservation and restoration to climate change mitigation in Indonesia. *Global Change Biology*;2022; 28(15): 4523-4538.
2. Arifanti VB, Novita N, Tosiani A. Mangrove deforestation and CO2 emissions in Indonesia. In *IOP Conference Series: Earth and Environmental Science*;2021; 874(1): 012006)
3. Acharya S, Jali P, Pradhan M, Pradhan C, Mohapatra PK. Antimicrobial and Antioxidant Property of a True Mangrove Rhizophora apiculata Bl. *Chemistry & Biodiversity*;2023; 20(9): e202201144.
4. Madagi SB, Hoskeri JH, Vedamurthy AB. Phytochemical profiling, in-vitro antioxidant and anti-inflammatory activities of Hopea ponga, Kandelia candel, Vitex leucoxydon and Rhizophora apiculata. *Journal of Pharmacognosy and Phytochemistry*;2018; 7(6): 1425-1440.
5. Sies H. Oxidative stress: Concept and some practical aspects. *Antioxidants*;2020; 9(9): 852.
6. Hapsari D, Nainggolan O, Kusuma D. Hotspots and regional variation in smoking prevalence among 514 districts in Indonesia: Analysis of basic health research 2018. *Global Journal of Health Science*;2020; 12(10).
7. Lee S, Kang S, Joo YS, Lee C, Nam KH, Yun HR, Han SH. Smoking, smoking cessation, and progression of chronic kidney disease: results from KNOW-CKD study. *Nicotine and Tobacco Research*;2021; 23(1): 92-98.
8. Ammirati AL. Chronic kidney disease. *Revista da Associação Médica Brasileira*;2020; 66: s03-s09
9. Mustofa S, Hanif F. The protective effect of Rhizophora apiculata bark extract against testicular damage induced by cigarette smoke in male rats. *Acta biochimica indonesiana*;2019; 2(1): 23-31.
10. Mustofa S, Ciptaningrum I, Zuya CS. Subacute toxicity test of Rhizophora apiculata bark extract on liver and pancreas histopathology of rats. *Acta Biochimica Indonesiana*;2020; 3(2):

- 89-97.
11. Mustofa S, Bahagia W, Kurniawaty E, Rahmanisa S, Audah KA. The effect of mangrove (*Rhizophora apiculata*) bark extract ethanol on histopathology pancreas of male white rats Sprague Dawley strain exposed to cigarette smoke. *Acta Biochimica Indonesiana*;2018; 1(1): 7-13.
 12. Kucukler S, Benzer F, Yildirim S, Gur C, Kandemir FM, Bengu AS, Dortbudak MB. Protective effects of chrysin against oxidative stress and inflammation induced by lead acetate in rat kidneys: a biochemical and histopathological approach. *Biological Trace Element Research*;2021; 199(4): 1501-1514.
 13. Ito K, Maeda T, Tada K, Takahashi K, Yasuno T, Masutani K, Nakashima H. The role of cigarette smoking on new-onset of chronic kidney disease in a Japanese population without prior chronic kidney disease: Iki epidemiological study of atherosclerosis and chronic kidney disease (ISSA-CKD). *Clinical and Experimental Nephrology*;2020; 24:919-926.
 14. Zheng CM, Lee YH, Chiu IJ, Chiu YJ, Sung LC, Hsu YH, Chiu HW. Nicotine causes nephrotoxicity through the induction of nlrp6 inflammasome and alpha7 nicotinic acetylcholine receptor. *Toxics*;2020; 8(4): 92.
 15. Mustofa S, Fahmi ZY. Efek Protektive Kardiovaskular Ekstrak *Rhizophora apiculata* Berbagai Pelarut pada Tikus yang Dipaparkan Asap Rokok. *Jurnal Kedokteran Universitas Lampung*;2021; 5(1): 7-15.
 16. Mustofa S, Anisya V. Efek Hepatoprotektif Ekstrak Etanol *Rhizophora Apiculata* Pada Tikus Yang Dipaparkan Asap Rokok. *Jurnal Kedokteran Universitas Lampung*;2020; 4(1): 12-17.
 17. Hong YA, Park CW. Catalytic antioxidants in the kidney. *Antioxidants*;2021; 10(1): 130.
 18. Arulkumar A, Kumar KS, Paramasivam S. Antibacterial and invitro antioxidant potential of Indian mangroves. *Biocatalysis and Agricultural Biotechnology*;2020; 23: 101491.
 19. Chan EWC, Lim WY, Wong CW, Ng YK. Some notable bioactivities of *Rhizophora apiculata* and *Sonneratia alba*. *ISME/GLOMIS Electron J*;2022; 20(4): 23-6.